

Back to Basics – the chest radiograph in silica associated tuberculosis

ABSTRACT

Silicosis increases the risk of tuberculosis (TB) but its presence complicates the radiological features of TB and they may not be typical. Additionally, HIV infection rates may be high in silica exposed populations and the prevalence of smear-negative pulmonary TB is higher in these groups. Consequently the chest radiograph – along with symptoms and other investigations – is important in identifying TB. The radiological features in reading chest radiographs for TB in the presence of silicosis are highlighted in the article to promote the earlier investigation of suspect cases.

Key words: tuberculosis, silicosis, radiological features, chest radiographs, tuberculosis detection

INTRODUCTION

Silicosis increases the risk of tuberculosis (TB) and the disease is common in individuals with the pneumoconiosis, particularly in settings with high background rates and when the silicosis is advanced. Consequently, TB should be considered in all cases of silicosis both for individual treatment and to reduce transmission. But, the presence of silicosis complicates the radiological features of TB and they may not be typical. Additionally, HIV infection rates may be high in silica exposed populations and the prevalence of smear-negative pulmonary TB is higher in these groups. Consequently the chest radiograph – along with symptoms and other investigations – is important in identifying TB. This article briefly summarises the epidemiology of silica and TB and highlights some of the radiological features in reading chest radiographs for TB in the presence of silicosis to promote the earlier investigation of suspect cases.

BACKGROUND EPIDEMIOLOGY

Exposure to silica is very common around the world with millions of people over-exposed in a large range of industries.¹ Silicosis burdens are high in some settings in southern Africa. For example, about 20% of long-service gold miners have the disease²; 22–36% of living ex-miners^{3,4,5} and cumulative prevalences can exceed 50% in miners followed to death.⁶ The proportion of miners with silicosis coming to autopsy at the National Institute for Occupational Health has increased markedly from 1975 to 2007: 3% to 32% in black miners and 18% to 22% in white miners.⁷

A major concern related to silicosis is the associated increased risk of TB, which approaches or equals that conferred by HIV infection.⁸ A seven-year follow-up of gold miners before the HIV epidemic found a relative risk of TB in men with silicosis compared to those without of 2.8 (95% CI 1.9–4.1), and the incidence of TB rose with increasing severity of silicosis: 2.2% per annum in mild silicosis to 6.3% per annum in those with advanced disease.⁹ The HIV epidemic has worsened the situation both

because of the high HIV prevalences in southern African workforces and because there is a multiplicative interaction for TB between silicosis and HIV; the risk of TB is higher than the sum of each risk combined.¹⁰ Importantly, silica exposure is associated with TB even in the absence of silicosis^{11,12} and the increased risk of active TB is life-long.¹¹ Consequently, very high burdens of TB have been described in silica-exposed populations: for example incidences between 3000 to 7000/100 000/year in gold miners¹³; and a prevalence of radiological TB of 6.5% in children (less than 10 to 18 years) living – and possibly working – in a community processing agate in India.¹⁴ In addition to miners, significantly increased risks for TB have been reported in stone crushers, foundry workers, construction, and stone masons.¹⁵

THE IMPORTANCE OF THE CHEST X-RAY

Sputum staining and culture remain the major modalities for the detection of active TB in workers exposed to silica, but the chest X-ray has an important place. Some of the reasons are:

1. an increased prevalence of smear-negative TB is found in HIV infected populations, but importantly patients with smear-negative disease can still transmit the infection¹⁶;
2. chest X-ray has been shown to greatly increase the sensitivity of screening for TB among HIV infected gold miners¹⁷;
3. active TB case detection, including regular chest X-rays, is recommended, resources permitting, for silica exposed workers partly because TB case-fatality rates have been found to be lower in workers detected by active radiological screening compared to self-presentation¹⁸; and
4. significant prevalences of multidrug resistant TB have been found among silica exposed miners: in the most recent study 4.3%¹⁹; and in earlier studies 2.3%²⁰ and 5.8%.²¹

Early diagnosis is important in reducing transmission.

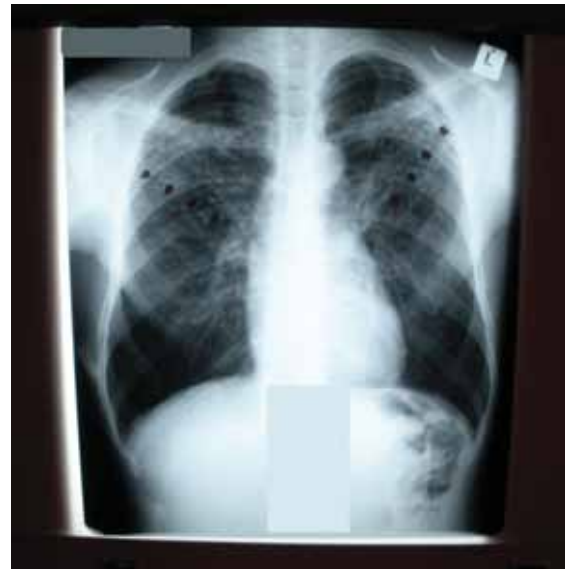
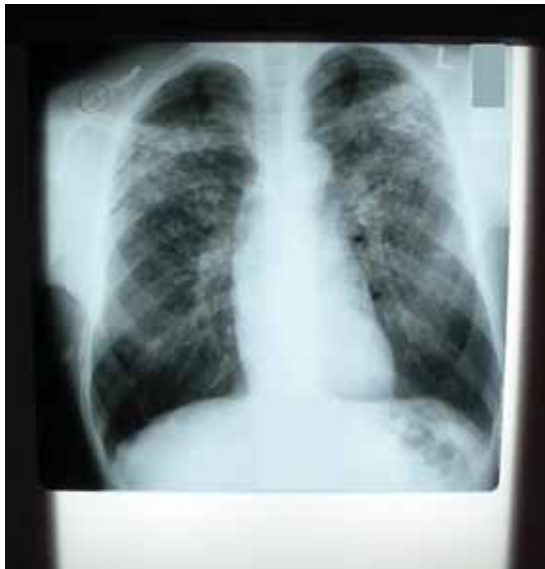Albert Solomon^{1,2}
MBBCH, D MED, DMR
(D), FC Rad (SA) DIAG,
MMed (Rad D) and
David Rees^{1,3} MBBCH,
DOH, MSc (Med) PhD

¹ National Institute for Occupational Health, National Health Laboratory Service.

² Professor Emeritus, University of the Witwatersrand.

³ Professor of Occupational Health, School of Public Health, University of the Witwatersrand.

Corresponding author:
Prof. Albert Solomon
NIOH, PO Box 4788,
Johannesburg 2000
Tel: +27 (0)11 712 6490
Fax: +27 (0)11 712 6531
E-mail: albert.solomon@nioh.nhls.ac.za



Florid examples of the nodular arrangement along the broncho-vascular bundles of silicosis and tuberculosis

The chest radiograph is thus valuable but only if radiological features of TB are identified, and these features may not be typical in patients with silicosis. Unfortunately, clinico-pathological studies show that high percentages of patients with active TB are not diagnosed in life. Data on 350 miners showed that clinicians failed to diagnose active TB in 65% of cases coming to autopsy.²² A study in four settings (two South African platinum mine hospitals, a South African teaching hospital and a London teaching hospital) found that PTB was missed in life in 51% of those patients who came to autopsy.²³ Many omissions may explain the delayed, incorrect and missed diagnosis of TB but one contributing factor is probably failure to detect the radiologic features of TB on the chest radiograph, especially when atypical.

THE RADIOLOGICAL FEATURES OF SILICOSIS AND TUBERCULOSIS IN SILICOSIS

Typically silicosis manifests radiologically as bilateral, uniformly distributed and sized, small rounded nodules (opacities) between 1–3 mm in size in the upper halves of the lungs.¹ In very early disease the opacities may appear first in the right upper zone. As silicosis advances the opacities may extend to the lower zones of the lungs and increase in size.

Radiographic TB might well be considered in three forms:

1. the typical and well-known active TB;
2. recurrent TB in a scarred lung following cure of a previous episode of the disease; and
3. an indolent (smouldering) state, particularly found in the nodular presentation of TB and silicosis.

Hence the radiologic features are numerous, but what follows highlights the features to look out for in silica-exposed workers, particularly those with silicosis because especially in the indolent form sputum smear and even

culture may remain persistently negative. The reason for this is that nodular TB and silicosis are sited in the interstitial compartment of the lung, and they accordingly lack airway contact. The chest radiograph therefore becomes extremely important.

In assessing the chest radiograph of silica exposed workers it is essential to have chronological details of exposure. The appearance of nodules unusually soon after first exposure should alert the reader to the likely possibility of TB. "Unusually soon" is difficult to define as very high levels of exposure produce silicosis in under 10 years, but this period would be the exception and should not be accepted as silicosis without further clinical investigation.

Sudden changes in radiological features, for example from one year to the next, are unusual in silicosis and should alert the practitioner to possible TB. Aspects of the radiologic presentation of silicosis and TB have been described elsewhere^{24,25} so are summarised here. In TB concurrent with silicosis the bilateral uniform profusion of nodular silicosis on the chest X-ray is likely to be disorganised giving way to a mixed pattern. A florid or subtle arrangement of nodules along a broncho-vascular bundle is a not uncommon feature. Regional aggregation of irregular-sized nodules on a background of established silicosis is highly suspicious of associated TB. Nodules in unexpected sites, for example the supra-clavicular region, are questionable, as typically silicosis spares these areas, unless very profuse. Variable profusions and opacities which are not evenly distributed in both lungs are suspect. Large opacities (i.e. radiologic opacities >1 cm) in silicosis require special attention as their appearance is often TB-associated. A miliary or peribronchiolar nodular superimposition on the silicotic nodular changes is often subtle and missed by the unwary with the possible fatal outcome associated with untreated miliary TB or non-recognition of bronchogenic disseminated TB. Mediastinal lymphadenopathy is rarely found in silicosis²⁶.

**“ . . . in the indolent form sputum smear and even culture
may remain persistently negative.”**

This finding on the X-ray in HIV positive patients is associated with smear-negative TB.¹⁶

CONCLUSION

The subtle or florid changes of TB are regularly superimposed on the radiographic appearance of silicosis. Knowledge of the kaleidoscopic features of pulmonary TB is essential in evaluating the chest radiograph of workers exposed to silica dust. Casual readers are likely to be at a disadvantage. Reading skill depends on the quality of X-rays, reading conditions and reading experience of chest radiographs in silicosis associated TB possibly with HIV present. Preferably well trained, knowledgeable and experienced chest readers are required to protect the worker from the consequence of missed active TB. Although the TB may be active the likelihood of a negative smear is high. The abnormal radiographic features should encourage the clinician to take a more aggressive approach in attempts to prove the existence of an active treatable TB.

LESSONS LEARNED

- Silicosis complicates the radiological features of TB and they may not be typical.
- Although the TB may be active the likelihood of a negative smear is high.
- It is essential to have chronological details of exposure.
- The appearance of nodules unusually soon after first exposure could indicate TB.
- The bilateral uniform profusion of nodular silicosis on the chest X-ray is likely to be disorganised giving way to a mixed pattern.
- Mediastinal lymphadenopathy is rarely found in silicosis.

REFERENCES

1. Rees D, Murray J. Silica, silicosis and tuberculosis. *Int J Tuberc Lung Dis*. 2007;11(5):474-484.
2. Churchyard GJ, Ehrlich RI, teWaterNaude JM, Pemba L, Dekker K, Vermeijs M et al. Silicosis prevalence and exposure-response relations in South African goldminers. *Occup Environ Med*. 2004;61(10):811-816.
3. Steen TW, Gyi KM, White NW, Gabosianelwe T, Ludick S, Mazonde GN, et al. Prevalence of occupational lung disease among Botswana men formerly employed in the South African mining industry. *Occup Environ Med*. 1997;54(1):19-26.
4. Trapido AS, Mqoqi NP, Williams BG, White NW, Solomon A, Goode RH, et al. Prevalence of occupational lung disease in a random sample of former mineworkers, Libode district, Eastern Cape Province, South Africa. *Am J Ind Med*. 1998;34(4):305-313.
5. Girdler-Brown BV, White NW, Ehrlich RI, Churchyard GJ. The burden of silicosis, pulmonary tuberculosis and COPD among former Basotho goldminers. *Am J Ind Med*. 2008;51(9):640-647.
6. Hnizdo E, Sluis-Cremer GK. Risk of silicosis in a cohort of white South African gold miners. *Amer J Ind Med*. 1993;24(4):447-457.
7. Nelson G, Girdler-Brown B, Ndlovu N, Murray J. Three decades of silicosis: disease trends at autopsy in South African gold miners. *Envir Health Perspect*. 2010;118(3):421-426.
8. American Thoracic Society. Targeted tuberculin testing and treatment of latent tuberculosis infection. *Am J Respir Crit Care Med*. 2000;161:S221-S247.
9. Cowie RL. The epidemiology of tuberculosis in gold miners with silicosis. *Am J Respir Crit Care Med*. 1994;150(5):1460-1462.
10. Corbett EL, Churchyard GJ, Clayton TC, Williams BG, Mulder D, Hayes RJ, et al. HIV infection and silicosis: the impact of two potent risk factors on the incidence of mycobacterial disease in South African miners. *AIDS*. 2000;14(17):2759-2768.
11. Hnizo E, Murray J. Risk of pulmonary tuberculosis relative to silicosis and silica exposure. *Occup Environ Med*. 1998;55:496-502.
12. teWaterNaude JM, Ehrlich RI, Churchyard GJ, Pemba L, Dekker K, Vermeijs M, et al. Tuberculosis and silica exposure in South African gold miners. *Occupational Environ Med*. 2006;63(3):187-192.
13. Department of Health, South Africa. Draft Tuberculosis Strategic Plan for South Africa 2007-2011. Pretoria: DoH; 2007.
14. Saiyed HN. Silicosis among children in the agate industry. In: Section VI Case Studies. Geneva, Switzerland: World Health Organization; 2005. p. 277-280. http://whqlibdoc.who.int/publications/2005/9241562927_section6_eng.pdf
15. National Institute for Occupational Safety and Health. Health effects of occupational exposure to respirable crystalline silica. Cincinnati: NIOSH; 2002.
16. Kanaya AM, Glidden DV, Chambers HF. Identifying pulmonary tuberculosis in patients with negative sputum smear results. *Chest*; 2001;120(2):349-355.
17. Day JH, Charalabous A, Fielding KL, Hayes RJ, Churchyard GJ, Grant AD. Screening for tuberculosis prior to isoniazid preventive therapy among HIV-infected gold miners in South Africa. *Int J Tuberc Lung Dis*. 2006;10(5):523-9.
18. Churchyard GJ, Kleinschmidt I, Corbett EL, Murray J, De Cock KM. Factors associated with an increased case-fatality rate in HIV-infected and non-infected South African gold miners with pulmonary tuberculosis. *Int J Tuberc Lung Dis* 2000;4(8):705-712.
19. Calver AD, Falmer AA, Murray M, Strauss OJ, Streicher EM, Hanekom M, et al. Emergence of increased drug resistance and extensively drug-resistant tuberculosis despite treatment adherence, South Africa. *Emerging Infectious Diseases*. 2010;16(2):264-271.
20. Churchyard G J, Corbett EL, Kleinschmidt I, Mulder D, De Cock KM. Drug-resistant tuberculosis in South African gold miners: incidence and associated factors. *Int J Tuberc Lung Dis*. 2000;4(4): 433-440.
21. Murray J, Sonnenberg P, Shearer S, Godfrey-Faussett P. Drug-resistant pulmonary tuberculosis in a cohort of southern African goldminers with a high prevalence of HIV infection. *S Afr Med J*. 2000;90(4): 381-386.
22. Murray J, Back P, Lowe P, Coetzee L. Clinico-pathological study to reduce the rate of missed and misdiagnosis of pulmonary tuberculosis in the South African mining industry. SIM Health 611. Johannesburg: Mine Health and Safety Council; 2000.
23. Field N, Murray J, Wong M, Dowdeswell R, Dudumayo N, Rametsi L, et al. Application of a review tool to improve diagnosis of pulmonary TB. 39th Union World Conference on Lung Health, Paris; 2008.
24. Solomon A, Rees D, Felix M, Venter E. A proposed radiographic classification of tuberculosis to accompany the ILO international classification of radiographs of pneumoconiosis. *Int J Occup Environ Health*. 2000;6(3): 215-219.
25. Solomon A. Silicosis and tuberculosis. Part 2 - A radiologic presentation of nodular tuberculosis and silicosis. *Int J Occup Environ Health*. 2001;7(1):54-57.
26. Ehrlich RI, Rees D, Zwi AB. Silicosis in non-mining industry on the Witwatersrand. *S Afr Med J*. 1988;73(12):704-708.